Bone Marrow Aspiration: Technique, Grafts, and Reports

Dennis Smiler, DDS, MScD,* and Muna Soltan, DDS†

This article describes a technique for obtaining adult stem cells from bone marrow aspirate. Case reports show how this procedure might replace the gold standard for bone grafts with the platinum standard of obtaining stem cells. The bone marrow aspirate and transplantation of adult stem cells within the resorbable) matrix and under the influence of soluble regulators have the potential for introducing the platinum standard for bone grafts. There are several advantages to using bone marrow aspirate. The technique is simple, a second surgical site is not needed, there is minimal postoperative morbidity, and adult stem cells populate the graft site with osteoblasts. (Implant Dent 2006; 15:229–235)

Key Words: adult stem cells, aspirant, bone graft, surgery, autogenous bone

There are 4 main elements necessary for successful bone grafts of the mandible and maxilla: soluble regulators, a resorbable matrix, stabilization of the matrix during healing, and cells. Soluble regulators are acquired from the blood. An abundance of resorbable matrices are available to the surgeon. Stabilization of the matrix can be achieved with guided resorbable membranes, titanium mesh, bone tacks, and screws. However, cells are the most critical component of a successful bone graft. More specifically, osteoblasts must populate the matrix in sufficient quantity to form bone.[1]

Cells are the answer. Without osteoblasts or precursor cells, bone will not form.[2,3] The "gold standard" for bone grafts suggests that harvested autogenous bone will provide osteoblasts.[4,5] A recent article by Soltan *et al*[6] presents the rationale and method of obtaining adult stem cells from bone marrow aspirate that differentiates to osteoblasts.

Bone is encircled by periosteum of dense connective tissue that contributes to the generation of osteoblast. It has 2 layers: an outer fibrous layer with typical fibroblasts; and an inner cellular layer, which contains osteoprogenitor cells that are capable of contributing to osteoblasts.[7,8] In addition, a layer of cells called the endosteum (endosteal cells) lines the marrow surface of compact bone. Like the periosteal cells, these endosteal cells are also osteoprogenitor cells capable of becoming osteoblasts.[9]

*Private practice, Encino, CA.
†Private practice, Riverside, CA.

ISSN 1056-6163/06/01503-229
Implant Dentistry
Volume 15 • Number 3

DOI: 10.1097/01.id.0000236125.70742.86

Osteoblasts and/or adult stem cells or primitive mesenchymal cells may also be present in the cancellous compartment of the recipient site. Osteoblasts are also found in adjacent decorticated bone, harvested autogenous bone, circulating blood, or bone marrow aspirate. If osteoblasts are not present at the recipient site, they must be harvested as a graft material.[10] The absence of osteoblasts will cause graft failure.

Stem Cells

By definition, stem cells are capable of both self-renewal and differentiation into a mature cell type. Stem cells divide to form one daughter cell that goes on to differentiate and one daughter cell that retains its stem cell properties. Classification of stem cells is based on their species of origin, tissue of origin, or differentiation capability of ≥1 specific type of the mature cells.[11] Some stem cells are more pluripotent than others. For example, all cells within the early embryo are totipotent up until the 16-cell stage or so and are thought to be the only single cells capable of differentiating into any cell type.[12,13] Adult stem cells are pluripotent but have more limited differentiation ability and, thus, are considered multipotent. Multipotent stem cells are only committed to differentiate to a limited number of types of cells that have a specific function (*e.g.*, cells that contribute to all the cells of the blood [hematopoietic stem cells] and other committed stem cells, such as mesenchymal stem cells). Mesenchymal stem cells are multipotent, reside in the bone marrow of adult human beings, and have differentiated into bone, fat, muscle, cartilage, and neurons.[14] These cells have been used to repair successfully a large cranial defect in a human patient.[15] Where do we find mesenchymal stem cells, osteoblasts, and the precursor for osteoblasts?

Bone Marrow

Bone marrow is found in the center of large flat bones and can be transplanted. Bone marrow contains abundant adult stem cells. Recent studies have shown that adult stem cells are more plastic than previously thought.[16] The term plasticity refers to the ability of adult stem cells to cross lineage barriers, and adopt the expression and function of other cell type.[17,18] It might be that adult stem cells hold the same clinical potential of embryonic stem cells, thus allowing researchers to bypass the ethical and practical issues related to the

preparation and use of embryonic stem cells.[19]

Bone marrow-derived stem cells include hematopoietic stem cells,[20,21] marrow stromal cells (mesenchymal stem cells),[22,23] and multipotent adult progenitor cells.[24,25] Bone marrow represents the main source of mesenchymal stem cells.[26] The hematopoietic cells are irreversibly committed toward a blood lineage, but other stromal cells can differentiate to form adipocytes, chondrocytes, osteoblasts, and other connective tissue cells.[27,28] Therefore, transplantation of marrow cells contributes to hematopoietic and osteogenic cells. A central issue concerning bone formation regards the developmental lineages of osteoblasts and osteoclasts. Osteoblasts derived from mesenchymal cells present in the skeletal environment: bone.[29] Osteoclasts are derived from blood-borne monocyte/macrophage cells.[30,31]

Living cells, particularly bone marrow cells, make cellular contributions to bone formation. Marrow cells promote osteogenesis.[32-34] Bone marrow contains osteoblast precursors that can differentiate into the mature osteoblasts that are needed to promote osteogenesis.[35] Developing a method and technique to harvest bone marrow and its osteoblastic precursor cells, and, subsequently, implant them into sites of impaired bone healing or bone-graft matrix might lead to a new approach, a "platinum standard" for bone regeneration.

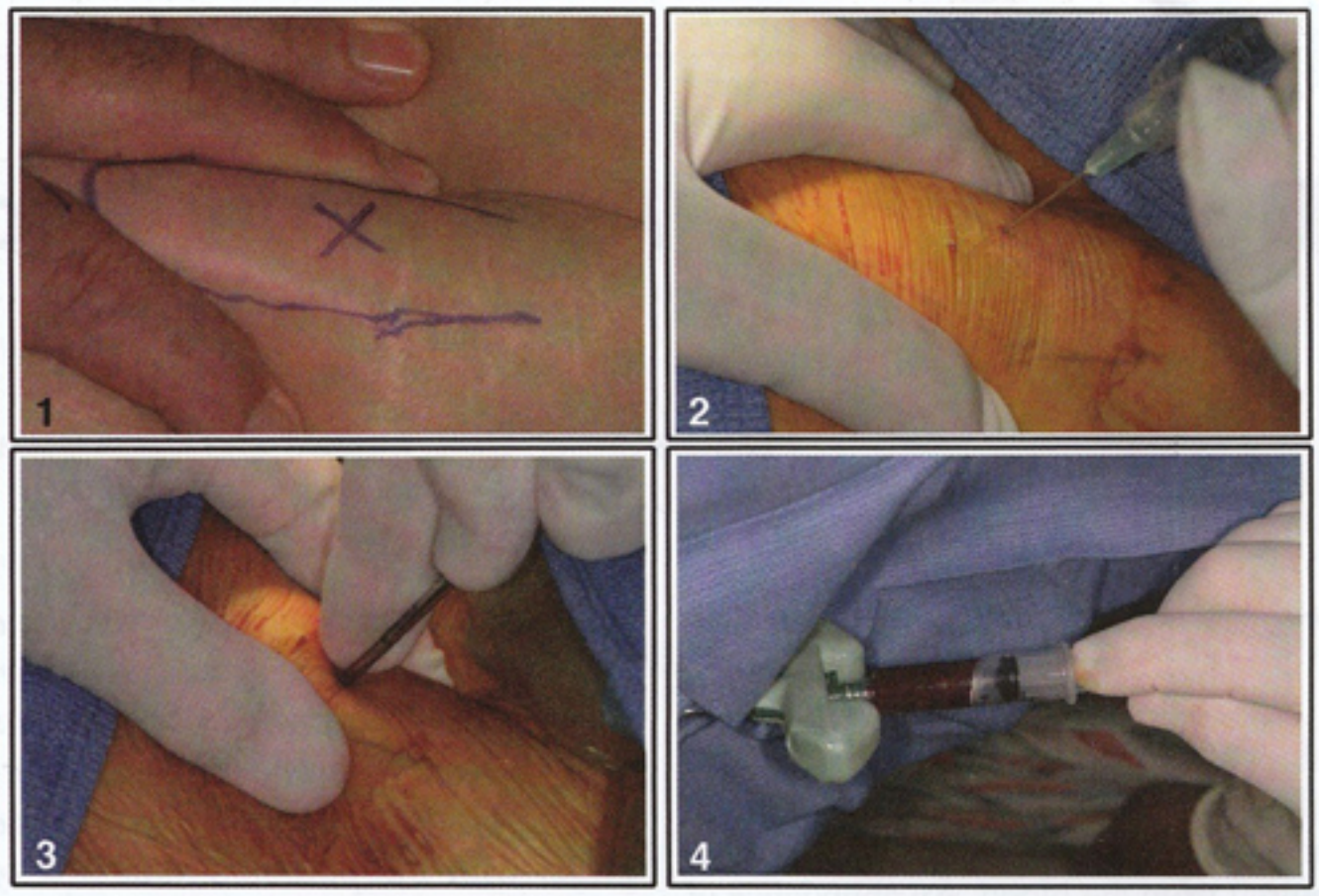

Fig. 1. Stretching the skin over the anterior and medial and lateral borders isolates the area for aspiration.
Fig. 2. The longer local anesthesia needle identifies the midpoint of the iliac crest and injects under the periosteum.
Fig. 3. The "J" needle inserts through the skin into the bone marrow compartment.
Fig. 4. The stylet is removed, syringe is connected, and 3–5 mL of bone marrow is aspirated.

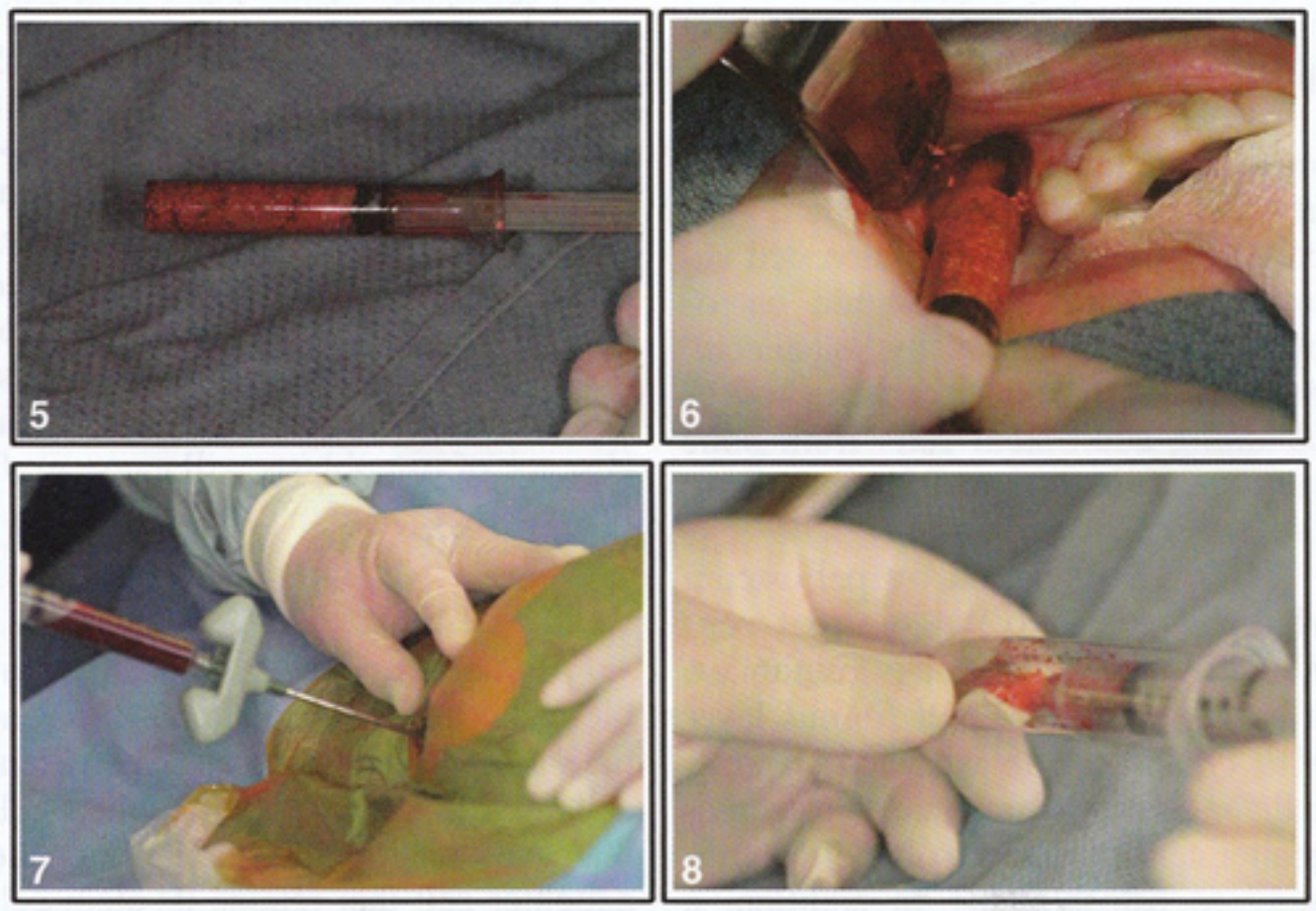

Fig. 5. Bone marrow aspirate and graft material are mixed.
Fig. 6. Sinus graft with loose compaction of graft.
Fig. 7. Placement of the needle through skin and into the marrow cavity to aspirate bone marrow.
Fig. 8. Bone marrow aspirate saturates the bone block when the plunger is pulled back.

Bone Marrow Aspiration Technique

The delivery of pluripotent mesenchymal stem cells within a resorbable matrix to induce osteogenesis has been successful.[36] The evidence that bone marrow fosters successful grafts is compelling and indicates that significant bone formation occurs when marrow is implanted in osseous defects.[37,38] Bone marrow can be extracted from the sternum, posterior ilium, or anterior ilium. The technique of autogenous bone marrow aspiration and grafting is virtually free of complications. Bone marrow aspiration and injection can be performed as outpatient procedures with the patient under oral sedated and local anesthesia, intravenous sedation, or general anesthesia.

Anterior Iliac Crest Bone Marrow Aspiration

The patient is lying in a prone position, and garments are removed to expose the anterior wing of the ilium. The border of the anterior wing is palpated. Palpation of the medial and lateral wall of the anterior ilium orients the site of needle puncture. The skin is stretched between 2 fingers over the bone crest identifying the thickness of the bone crest (Fig. 1). The anterior position of the iliac crest and site of needle puncture can be outlined. The site is prepared

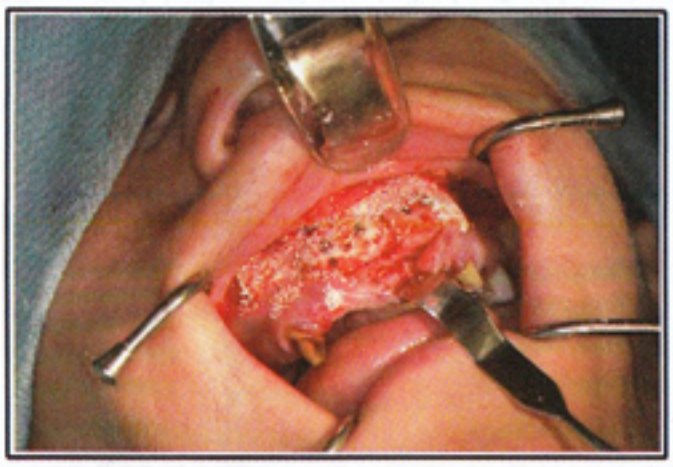

Fig. 9. Bone blocks are secured with screws, and particulate graft is mortised over the blocks.

with Betadine (Purdue Pharma L.P., Stamford, CT) solution, and an adhesive drape is placed over the aspiration site. Xylocaine (AstraZeneca Pharmaceuticals LP, Wilmington, DE) local anesthesia is placed under the skin. A longer needle is used to identify the midpoint of the iliac crest and deposit 3–4 mL 2% Xylocaine under the periosteum (Fig. 2).

A "J" needle (Jamshidi Bone Marrow Biopsy and Aspiration Tray; Cardinal Health, McGaw Park, IL) is inserted by hand through the skin into the anterior/posterior iliac wing (Fig. 3). The needle is rotated gently into 1 cm of the marrow cavity. The stylet is removed from the needle and a 5-cc syringe attached. Bone marrow is aspirated by retraction of the plunger of the syringe (Fig. 4). After 2–3 mL of marrow is collected, the needle can be repositioned if more marrow can be obtained, if needed. The marrow is aspirated with a glass syringe in 3–5-cc aliquots with repositioning of the needle after each aspiration. This procedure is performed to ensure that marrow is aspirated rather than venous blood. The syringe is removed from the needle, and the needle is removed from the marrow space with an upward twisting motion. Pressure is placed over the aspiration site for 5 minutes, and a bandage is placed.

Case No. 1. The bone marrow aspirate is mixed with resorbable matrix in a glass syringe (Fig. 5). After sinus-lift surgery to create the graft recipient site, the graft is deposited with loose compaction to reconstitute the buccal wall of the maxilla (Fig. 6).

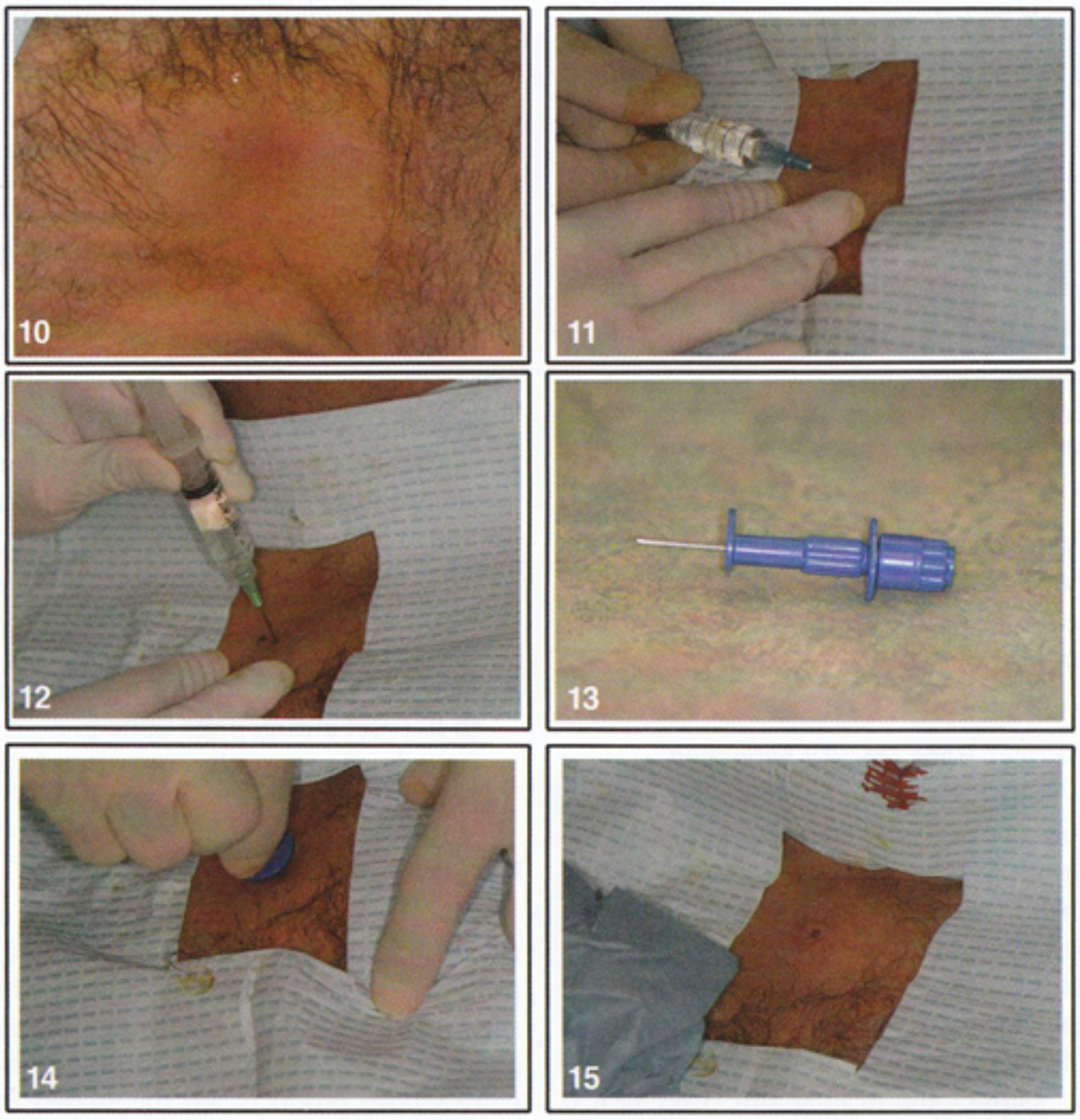

Fig. 10. The graft site below the suprasternal notch is shaved.
Fig. 11. Subcutaneous anesthesia is given.
Fig. 12. Anesthesia is delivered under the periosteum.
Fig. 13. The needle guard is locked to the distance of the local anesthesia needle.
Fig. 14. Twisting and downward pressure place the needle into the sternum cancellous bone.
Fig. 15. A small puncture remains after removal of the needle.

Posterior Iliac Crest Bone Marrow Aspiration

The patient is lying flat and turned onto the hip. The bottom leg is extended straight, and the upper leg is bent at the knee. The patient is prepared and draped as usual for this procedure. The juncture of the sacroiliac region is palpated, and the finger is moved up away from the space over the broad crest of the posterior iliac wing. Following injection of local anesthesia, the biopsy needle is placed through the skin, over the iliac crest, and rotated 1 cm into the marrow space. The stylet is removed, syringe is attached, and bone marrow aspirate is taken (Fig. 7).

Case No. 2. This 42-year-old female patient presents with partially edentulous maxilla. There is insufficient bone height of the right posterior maxilla for placement of implants. In addition, there is severe atrophy of the anterior maxilla. The treatment plan is sinus-lift subantral bone graft augmentation of the posterior maxilla. Bone graft of the anterior maxilla will add sufficient bone for implants to support fixed crown and bridge restorations.

The atrophic recipient site was prepared and decorticated. There were 2 cortico-cancellous allograft bone blocks contoured to fit the anterior recipient site. Care was taken not to over contour the bone blocks at the expense of the cancellous bone. Transosseous lag screws stabilized the bone blocks for contouring and decortication, with small fissure burs, of its cortical surface. The bone blocks were removed and placed in an occluded syringe. The bone marrow aspirate was placed in the syringe covering the bone block. The plunger was placed, the syringe inverted to expel air, and the needle port again occluded. Pulling back on the plunger created a vacuum and saturated the bone blocks with marrow aspirate (Fig. 8). Particulate resorbable matrix saturated with the

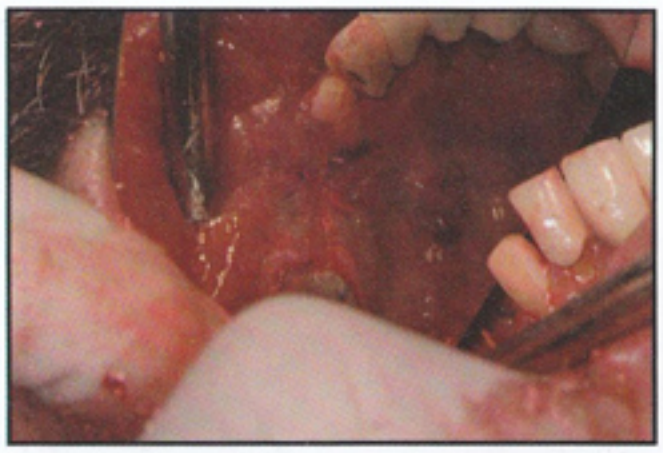

Fig. 16. The graft is placed into a recent extraction site, and the flap is sutured.

marrow aspirate was mortised over the bone blocks (Fig. 9). The mucoperiosteal flap was closed and sutured without tension on the incision.

Sternum Bone Marrow Aspiration

In this awake patient, the area of the sternum below the suprasternal notch is shaved and prepared in the usual manner (Fig. 10). Subcutaneous local anesthesia is given (Fig. 11). Approximately one inch below the notch, the needle finds the cortical plate of the sternum, and anesthesia is deposited under the periosteum (Fig. 12). It is important that the length of needle passing from skin to making contact with bone is noted and recorded. The needle guard of the syringe is locked to expose the length of needle as noted when giving local anesthesia (Fig. 13). This procedure is important so that the aspiration needle passes through only the outer cortex into the marrow space and not through the inner cortex into the aorta (Fig. 14). The syringe is connected to the needle after the stylet is removed and bone marrow drawn into the syringe. The needle is twisted as it is removed from the bone, leaving a small puncture (Fig. 15) that is covered with a Band-Aid (Johnson & Johnson, Somerville, NJ).

Case No. 3. A 52-year-old male presented with partially edentulous mandible and failing right canine, first bicuspid, and molar teeth. The indicated teeth were extracted, and the sockets debrided irrigated and decorticated of the dental lamina. The porous resorbable matrix was saturated with bone marrow aspirate and placed in the sockets. The mucoperiosteal flap was repositioned and sutured without tension (Fig. 16).

Conclusions

Using autogenous bone marrow grafts to promote osteogenesis in resorbable matrix has the following advantages:

1. Aspirated autogenous bone marrow used in conjunction with a resorbable allograft or xenograft matrix has ideal properties for stimulating bone osteoinduction and osteoconduction.
2. The aspiration technique is relatively simple and can be performed on an outpatient basis.
3. The need for an open surgical site to harvest autogenous bone is eliminated, along with any attendant complications.

Disclosure

Dr. Dennis Smiler claims to have a financial interest in Dentsply, CeraMed, as a consultant, whose products are shown in this article. Dr. Muna Soltan claims to have no interest in any company whose products are mentioned in this article.

References

1. Smiler DG, Soltan M. The bone-grafting decision tree: A systematic methodology for achieving new bone. *Implant Dent.* 2006;15:122-127.
2. McCain JP, Marx RE. A retrospective study of the donor site in bone grafts from the ilium. Read before the AAOMS 60th Annual Meeting, Quebec City, Quebec, June 14-17, 1978.
3. Burwell RG. Studies in the transplantation of bone. The fresh composite homograft autograft of cancellous bone. *J Bone Joint Surg.* 1964;46:110-140.
4. Burwell RG. Studies in the transplantation of bone. Treated composite homograft-autografts of cancellous bone: An analysis of inductive mechanisms in bone transplantation. *J Bone Joint Surg.* 1966;48:532-566.
5. Lindholm TS, Nilsson OS. Extraskeletal and intraskeletal new bone formation induced by demineralized bone matrix combined with marrow cells. *Clin Orthop Relat Res.* 1982;171:251-255.
6. Soltan M, Smiler D, Gallani F. A new "Platinum" standard for bone grafting: Autogenous stem cells. *Implant Dent.* 2005; 14:322-327.
7. Kawamura M, Urist MR. Induction of callus formation by implants of bone morphogenetic protein and associated bone matrix noncollagenous proteins. *Clin Orthop Relat Res.* 1988;236:240-248.
8. Reddi AH, Hascall VC. Changes in proteoglycan types during Imatrix-induced cartilage and bone development. *J Biol Chem.* 1978;253:2429-2436.
9. Lindhe J, Brånemark P-I. Observations on vascular proliferation in a granulation tissue. *J Periodontol Res.* 1970;5:276-292.
10. Smiler DG. Bone grafting: materials and modes of action. *Pract Periodontics Aesthet Dent.* 1998;8:413-416.
11. Herzog E, Chai L, Krause D. Plasticity of marrow-derived stem cells. *Blood.* 2003;102:3483-3493.
12. Benfu Li, in Song SY, Koo YM, Macer DRJ, eds. *Bioethics in Asia in the 21st Century.* Great Britain: BMJ Publishing Group; 2003:58-60.
13. Fraser CC, Szilvassy SJ, Eaves CJ, et al. Proliferation of totipotent hematopoietic stem cells in vitro with retention of long-term competitive in vivo reconstituting ability. *Proc Natl Acad Sci U S A.* 1992; 89:1968-1972.
14. Fukuchi Y, Nakajima H, Sugiyama D, et al. Human placenta-derived cells have mesenchymal stem/progenitor cell potential. *Stem Cells.* 2004;22:649-658.
15. Lendeckel S, Jödicke A, Christophis P, et al. Autologous stem cells (adipose) and fibrin glue used to treat widespread traumatic calvarial defects: Case report. *J Craniomaxillofac Surg.* 2004;32:370-373.
16. Schwartz RE, Reyes M, Koodie L, et al. Multipotent adult progenitor cells from bone marrow differentiate into functional hepatocyte-like cells. *J Clin Invest.* 2002;109:1291-1302.
17. Krause D, Cantley L. Bone marrow plasticity revisited: Protection or differentiation in the kidney tubule? *J Clin Invest.* 2005;115:1705-1708.
18. Krause DS, Theise ND, Collector MI, et al. Multi-organ, multi-lineage engraftment by a single bone marrow-derived stem cell. *Cell.* 2001;105:369-377.
19. Mariani S. Conference report–Stem cells and tissue engineering–Dreaming things that never were. Paper presented at: 7th Annual Meeting of the American Society of Gene Therapy; June 2-6, 2004; Minneapolis, MN.
20. McKinney-Freeman SL, Jackson KA, Camargo FD, et al. Muscle-derived hematopoietic stem cells are hematopoietic in origin. *Proc Natl Acad Sci U S A.* 2002; 99:1341-1346.
21. Kawada H, Ogawa M. Bone marrow origin of hematopoietic progenitors and stem cells in murine muscle. *Blood.* 2001;98:2008-2013.

22. Pittenger MF, Mackay AM, Beck SC, et al. Multilineage potential of adult human mesenchymal stem cells. *Science.* 1999;284:143-147.

23. Jiang Y, Jahagirdar BN, Reinhardt RL, et al. Pluripotency of mesenchymal stem cells derived from adult marrow. *Nature.* 2002;418:41-49.

24. Jiang Y, Vaessen B, Lenvik T, et al. Multipotent progenitor cells can be isolated from postnatal murine bone marrow, muscle, and brain. *Exp Hematol.* 2002;30: 896-904.

25. Gronthos S, Zannettino AC, Hay SJ, et al. Molecular and cellular characterization of highly purified stromal stem cells derived from human bone marrow. *J Cell Sci.* 2003;116:1827-1835.

26. Zhang Yi, Chang Li, Jiang X, et al. Comparison of mesenchymal stem cells from human placenta, bone marrow. *Chin Med J.* 2004;117:882-887.

27. Bianco P, Robey PG. Marrow stromal stem cells. *J Clin Invest.* 2000;105: 1663-1668.

28. Kuznetsov SA, Mankani MH, Gronthos S, et al. Circulating skeletal stem cells. *J Cell Biol.* 2001;153:1133-1140.

29. Parfitt AM. The bone remodeling compartment: A circulatory function for bone lining cells. *J Bone Miner Res.* 2001; 16:1583-1585.

30. Long MN, Robinson JA, Ashcroft SA, et al. Regulation of human bone marrow-derived osteoprogenitor cells by osteogenic growth factors. *J Clin Invest.* 1995;95:881-887.

31. Long MW, William JL, Mann KG. Expression of human bone-related proteins in the hematopoietic microenvironments. *J Clin Invest.* 1990;86:1387-1395.

32. Bereford JN. Osteogenic stem cells and the stromal system of bone and marrow. *Clin Orthop.* 1989;240:270-280.

33. Burwell RG. The function of bone marrow in the incorporation of a bone graft. *Clin Orthop.* 1985;200:125-141.

34. Chase SW, Herndon CH. The fate of autogenous and homogenous bone grafts. *J Bone Joint Surg.* 1955;37:809-826.

35. Kassem M, Mosekilde I, Rungby J, et al. Formation of osteoclasts and osteoblast-like cells in long-term human bone marrow cultures. *APMIS.* 1991;99: 262-268.

36. Helm GA, Dayoub H, Jane JA. Bone graft substitutes for the promotion of spinal arthrodesis. *Neurosurg Focus.* 2001;10:1-5.

37. Connolly JF, Guse R, Lippiello L. Development of an osteogenic bone marrow preparation. *J Bone Joint Surg.* 1989; 71:681-691.

38. Nade S. Clinical implications of cell function in osteogenesis. *Ann R Coll Surg Engl.* 1976;61:189-194.

Reprint requests and correspondence to:
Dennis G. Smiler, DDS, MScD
Suite 606
16661 Ventura Boulevard
Encino, CA 91436
E-mail: smiler@smiler.net

ID Abstract Translations

GERMAN / DEUTSCH

AUTOR(EN): Dennis Smiler, DDS, MScD,* Muna Soltan, DDS.** **Privat praktizierender Arzt, Encino, CA. **Privat praktizierender Arzt, Riverside, CA. Schriftverkehr: Dennis G. Smiler, DDS, MScD, 16661 Ventura Boulevard, Suite 606, Encino, California 91436. e-Mail: smiler@smiler.net. Muna Soltan, DDS, 4624 Arlington Avenue, Riverside, California 92504. e-Mail: soltan@sbcglobal.net*

Aspiration des Knochenmarks: **Technik, Berichte, Transplantate**

ZUSAMMENFASSUNG: Der vorliegende Artikel beschreibt eine Technik zur Gewinnung von ausgereiften Stammzellen durch Verwendung von Knochenmarksaspirat. In Fallstudien hat sich erwiesen, dass diese Verfahrenstechnik die ehemals als Optimum angesehene Methodik der Knochentransplantation durch Einsatz von Stammzellen als best mögliche Behandlungsmethode ablösen kann. Das Knochenmarksaspirat und die Transplantation von Stammzellen in einer resorbierbaren Matrix und unter dem Einfluss löslicher Regulatoren können diesen neuen optimalen Standard für Knochentransplantierungen möglich machen. Die Verwendung von Knochenmarksaspirat birgt einige Vorteile. Die Technik selbst ist unkompliziert, man verursacht keine zweite chirurgische Eingriffsstelle, die Erkrankungswahrscheinlichkeit nach dem Eingriff ist minimal und die Stammzellen bevölkern die Transplantierungsstelle mit Osteoblasten.

SCHLÜSSELWÖRTER: ausgereifte Stammzellen, Aspirat, Knochentransplantat, chirurgischer Eingriff, autogenes Knochengewebe

SPANISH / ESPAÑOL

AUTOR(ES): Dennis Smiler, DDS, MScD,* Muna Soltan, DDS.** **Práctica Privada, Encino, CA. **Práctica Privada, Riverside, CA. Correspondencia a: Dennis G. Smiler, DDS, MScD, 16661 Ventura Boulevard, Suite 606, Encino, California 91436. Correo electrónico: smiler@smiler.net. Muna Soltan, DDS, 4624 Arlington Avenue, Riverside, California 92504. Correo electrónico: soltan@sbcglobal.net*

La aspiración de la médula ósea: **Técnica, Informes, Injertos**

ABSTRACTO: Este artículo describe una técnica para obtener células madres adultas de la aspiración de la médula ósea. Los informes del caso muestran cómo este procedimiento podría reemplazar al procedimiento conocido para los injertos de hueso como la norma de platino para obtener células madres. La aspiración de la médula ósea y el trasplante de células madres adultas dentro de la matriz que se reabsorbe y bajo la influencia de reguladores solubles tienen el potencial de introducir la norma de platino en los injertos de hueso. Hay varias ventajas en el uso de la aspiración de la médula ósea. La técnica es simple, no se requiere un segundo sitio quirúrgico, existe una morbosidad postoperatoria mínima y las células madres adultas pueblan el sitio del injerto con osteoblastos.

PALABRAS CLAVES: **células madres adultas, injerto de hueso, cirugía, hueso autógeno**

PORTUGUESE / PORTUGUÊS

AUTOR(ES): Dennis Smiler, Cirurgião-Dentista, Mestre em Odontologia,* Muna Soltan, Cirurgião-Dentista.** **Clínica Particular, Encino, CA. **Clínica Particular, Riverside, CA. Correspondência para: Dennis G. Smiler, DDS, MScD, 16661 Ventura Boulevard, Suite 606, Encino, California 91436. Email: smiler@smiler.net. Muna Soltan, DDS, 4624 Arlington Avenue, Riverside, California 92504. Email: soltan@sbcglobal.net*

Aspiração de Medula Óssea: **Técnica, Relatos, Enxertos**

RESUMO: Este artigo descreve uma técnica para obter células-tronco adultas a partir de aspirado de medula óssea. Os relatos de caso mostram como esse procedimento poderia substituir o padrão de ouro de enxertos ósseos com o padrão de platina de obtenção de células-tronco. O aspirado de medula óssea e o transplante de células-tronco adultas dentro da matriz reabsorvível e sob a influência de reguladores solúveis têm o potencial de introduzir o padrão de platina para enxertos ósseos. Há várias vantagens em usar aspirado de medula óssea. A técnica é simples, um segundo local cirúrgico é necessário, há morbidez pós-operatória mínima e as células-tronco adultas povoam o local do enxerto com osteoblastos.

PALAVRAS-CHAVE: células-tronco adultas, enxerto ósseo, cirurgia, osso autógeno

JAPANESE / 日本語

Bone Marrow Aspiration：テクニック、報告、移植

著者：デニス・スマイラー、DDS、MScD*、ムナ・ゾルタン、DDS**

要約：本論文は成人stem cellsをbone marrow aspirateから採収する方法を説明する。これまでの骨移植のgold standardであった方法とって代わる可能性のある、stem cell採収法のplatinum standardの症例報告である。Soluble regulatorsのinfluenceを受けた吸収性基質内部のbone marrow aspirateと成人stem cell移植は、骨移植のplatinum standardとなる可能性がある。Bone marrow aspirateの使用にはいくつかの利点がある。それは、この方法が技術的にシンプルであり、2次surgical siteが不要であり、術後morbidityが非常に小さく、成人stem cellが移植部位を骨芽細胞でpopulateすることなどである。

キーワード：成人stem cell、aspirant、骨移植、自家骨

** エンシノ（カリフォルニア）で開業*
*** リバーサイド（カリフォルニア）で開業*

問い合わせ先：Dennis G. Smiler, DDS, MScD, 16661 Ventura Boulevard, Suite 606, Encino, California 91436
Eメール：smiler@smiler.net
問い合わせ先：Muna Soltan, DDS, 4624 Arlington Avenue, Riverside, California 92504
Eメール：soltan@sbcglobal.net

CHINESE / 中国語

骨髓穿刺：技巧、報告、移植

作者：Dennis Smiler，DDS.，MScD.*：Muna Soltan，DDS

摘要：本文描述從骨髓抽出液取得成人幹細胞的技巧。案例報告顯示此程序可能以鉑金標準的幹細胞取得替代黃金標準的骨移植。在可吸收基質內與在可溶解調節器的影響下，成人幹細胞骨髓抽出液與移植有引進骨移植鉑金標準的潛在可能。利用骨髓抽出液有多項優點，其技巧很簡單，不需要第二外科部位，僅有最低的術後發病率，而且成人幹細胞能以成骨細胞在移植部位繁殖。

關鍵字：成人幹細胞、抽出液、骨移植、外科手術、自體骨

** 加州恩西諾私人開業醫生*
*** 加州河濱郡私人開業醫生*

轉載申請與通訊方式：*Dennis G. Smiler, DDS, MScD, 16661 Ventura Boulevard, Suite 606, Encino, California 91436*
電郵信箱：smiler@smiler.net
轉載申請與通訊方式：*Muna Soltan, DDS, 4624 Arlington Avenue, Riverside, California 92504*
電郵信箱：soltan@sbcglobal.net